

**CASE STUDY FOR
LDT
RECERTIFICATION**

SUBMITTED BY

**PAULA NOYES OTR
LLCC**

E. S.

Patient's age at initial eval 82 year old Hispanic female.

History:

Status post B) knee replacements. R) knee with complications unresolved infection. Hardware removed and patient placed in Long Term Acute Care Hospital for R) total knee revision in 2007. Sent to TCCC for rehab on 5-15-2007.

Patient is also Diabetic Type II with a pacemaker and history of HTN.

Patient evaluated by OTR for ADL retraining, upper body strengthening.

Patient observed by this OTR ambulating in gym. Patient was wearing a dress and lower extremities were visible. No longer definition in legs from knees to ankles. Shape was cylindrical, deep red in color and texture of leather.

LDT commenced on 8-7-07 with measurements taken. Mapping indicated good lymphatic flow along expected pathways with exception of R) knee. Could not determine lymphatic flow to the anterior or posterior knee.

Treatment plan 5xweek. Series of 46 treatments.

Patient was educated on self drainage techniques and instructed to perform 2x daily.

Compression bandages were applied after each session. Patient enlisted the help from nursing to remove every evening prior to bedtime. Patient was compliant with self drainage and rolled all bandages for the next days session. Patient remained unwrapped on weekend. Kinesiotape was also applied along primary lymphatic channels.

All treatments were coordinated with wound care nurse as her dressing was changed daily.

Due to the weight of limbs initially patient required assist with lifting legs into and out of bed.

On 8-16-007 Patient reported that "Legs used to burn and hurt so bad." Fibrosis had decreased from max to mod in lower portion of B) legs. Unable to ambulate wth walker at this time due to limited ankle mobility.

9-04-2007 "You should have been here when I took the bandages off, my feet were normal".

9-5-2007 Measurements taken. A reduction of 25 cm L) 38.5 cm R)

9-20-2007 Measurements taken. A reduction of 32.5 L) 43 R)

Patient can now move legs in and out of bed and ambulates short distances with rolling walker. She is able to wear diabetic shoes. Arrangements were made to be fitted with Elvarex garments including toe caps. Patient was discharged home. Provided with information on facilities providing lymphatic drainage for both continued treatment and maintenance treatments.

Right knee wound had not healed at discharge. She was to pursue outpatient wound care.

12-10-2008

Patient readmitted to facility status post R) above the knee amputation.

She had been measured for Elvarex garments, however amputation was scheduled prior to purchase.

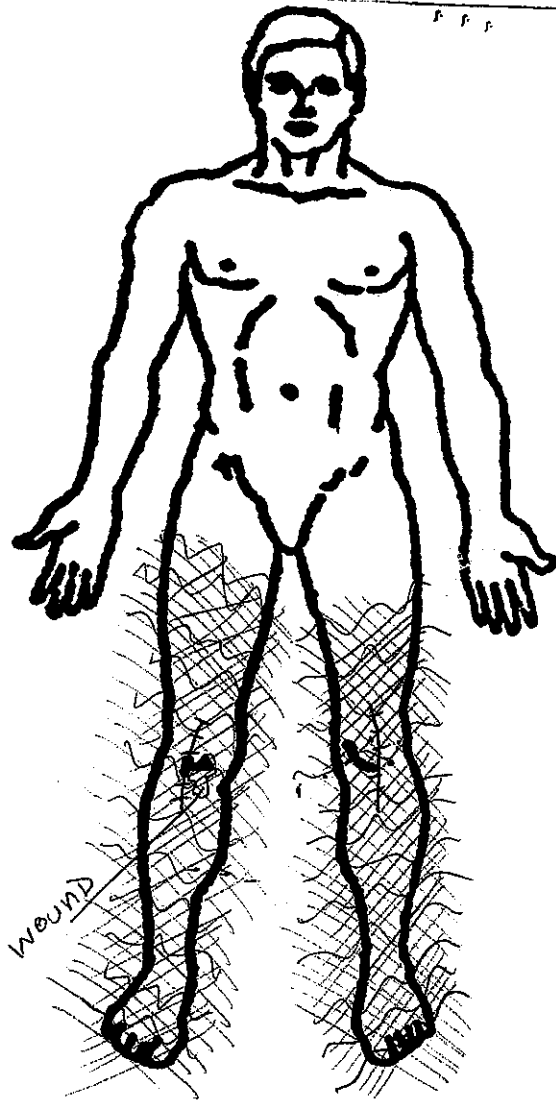
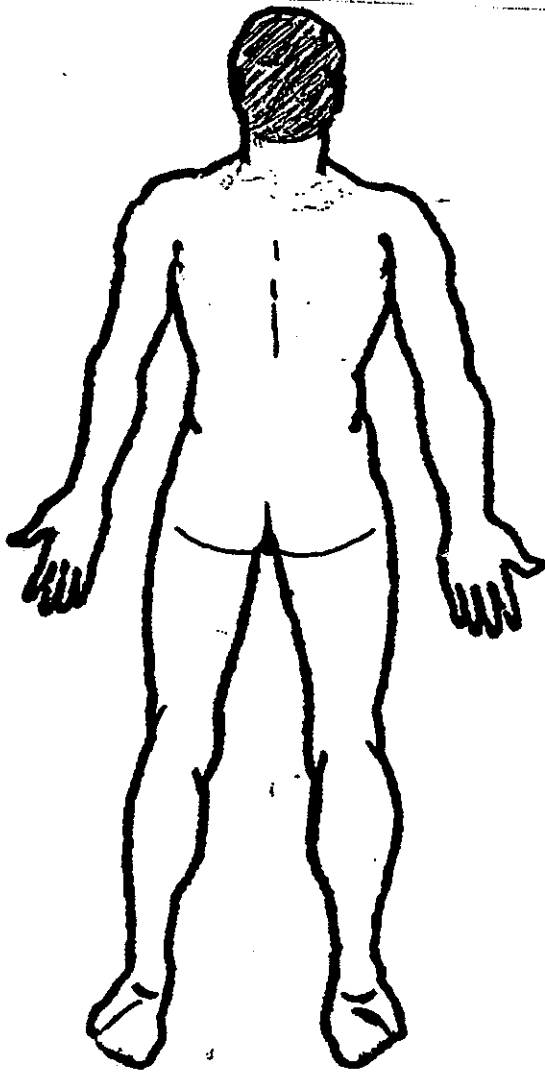
L) lower extremity, while not as engorged with fluid as on previous stay, was edematous with mild fibrosis.

Primary focus on this stay was to increase upper body strength, endurance in preparation for prosthetic fitting to resume functional mobility and return home. Lymphatic drainage performed 1-2 times per week as adjunct to

primary focus of Occupational therapy.

Patient began using prosthesis 3-01-2008 with rolling walker. Circumference of L) leg stabilized 3-17-2008. Patient was provided with Knee high compression garment 20-30mmhg which she could purchase upon discharge. Custom garments will not be an option for her secondary to cost.

Patients stay was from 12-10-2008 to 3-14-2008 with resolution of edema in L) LE. She independent with donning compression garment with use of donner. Secondary to ill fitting prosthesis, and Medicare coverage, she was discharged to rehab hospital for further rehabilitation.



REDNESS 

EDEMA 

WOUND 

FIBROSIS 

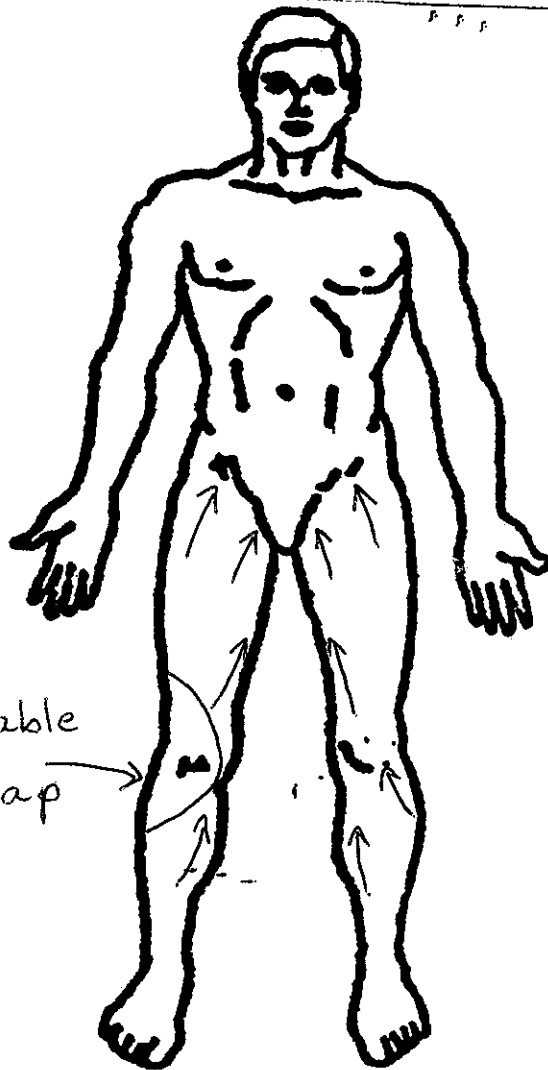
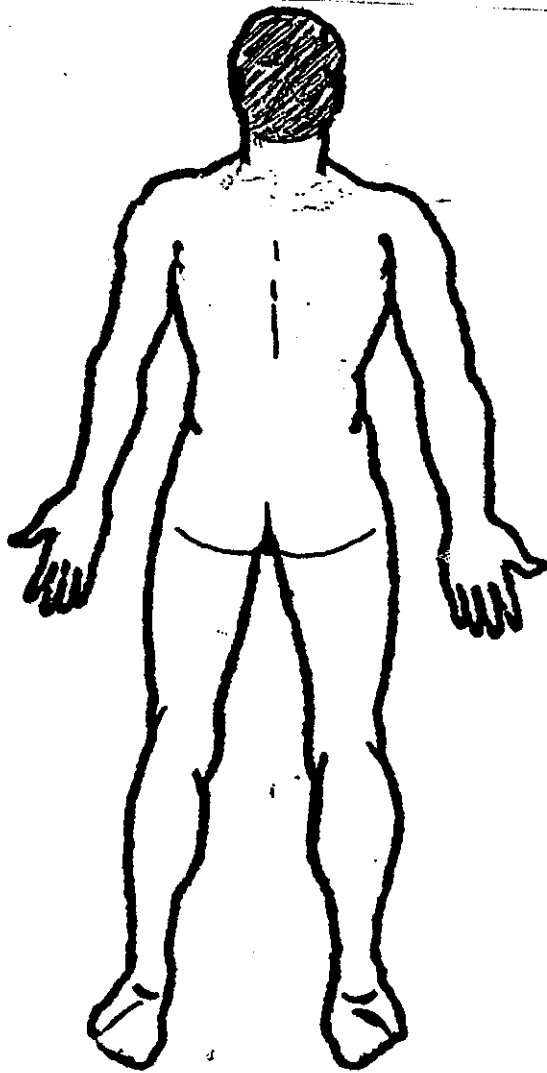
BRUISE 

SCAR 

PATIENT: S. [redacted]

ROOM#: 1810

DATE: 8-7-07



P P P

unable to map

REDNESS 

EDEMA 

WOUND 

FIBROSIS 

BRUISE 

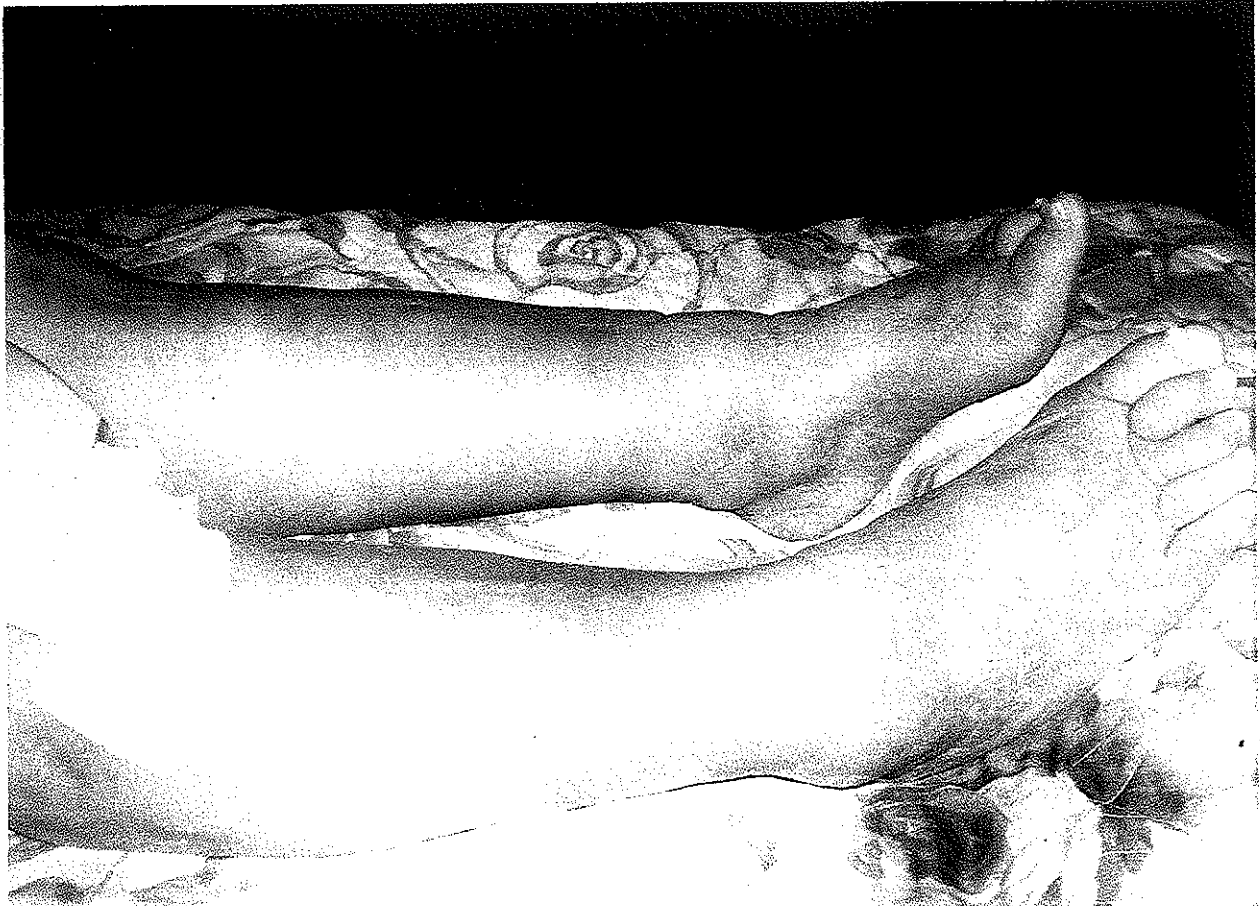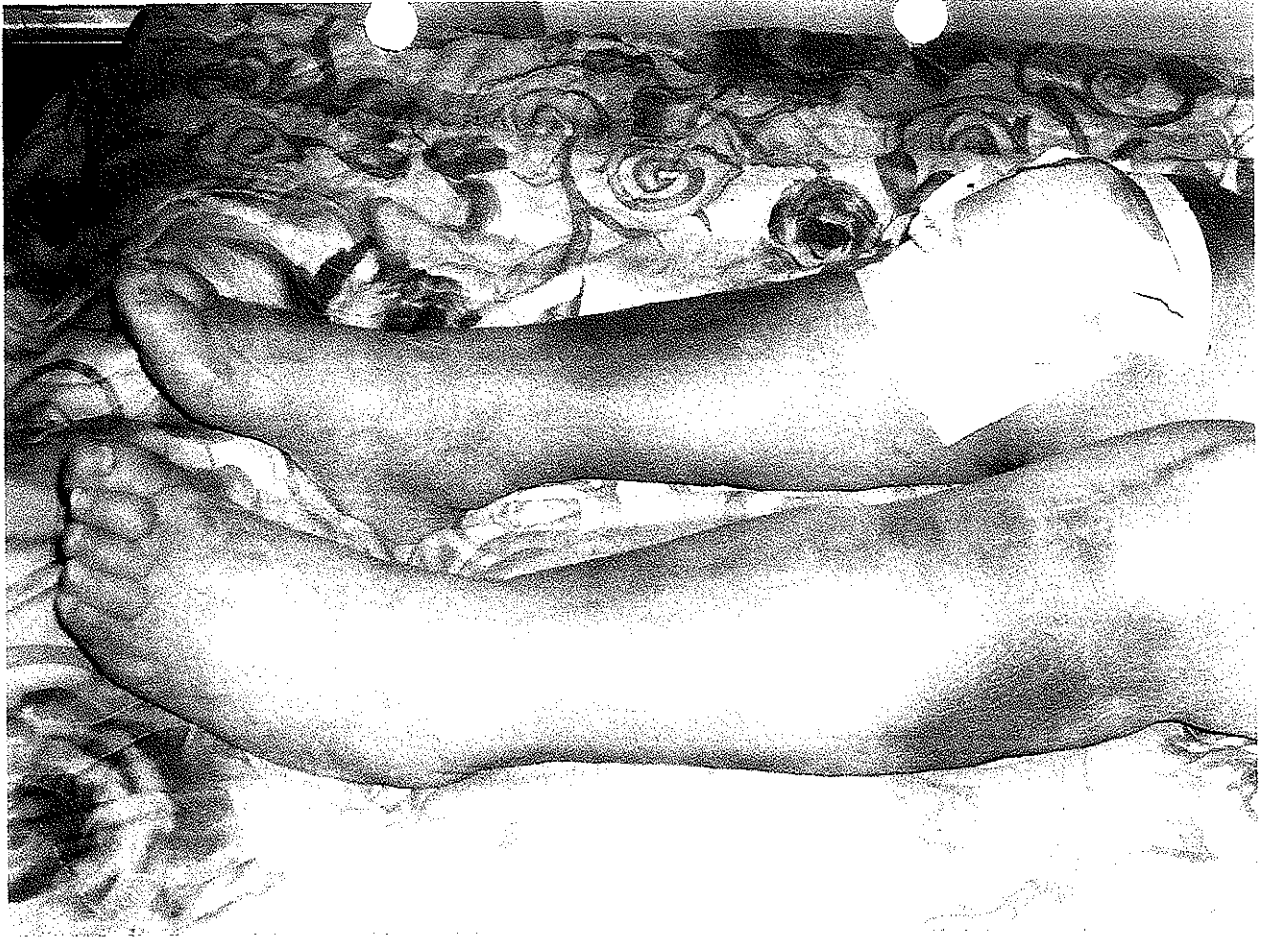SCAR 

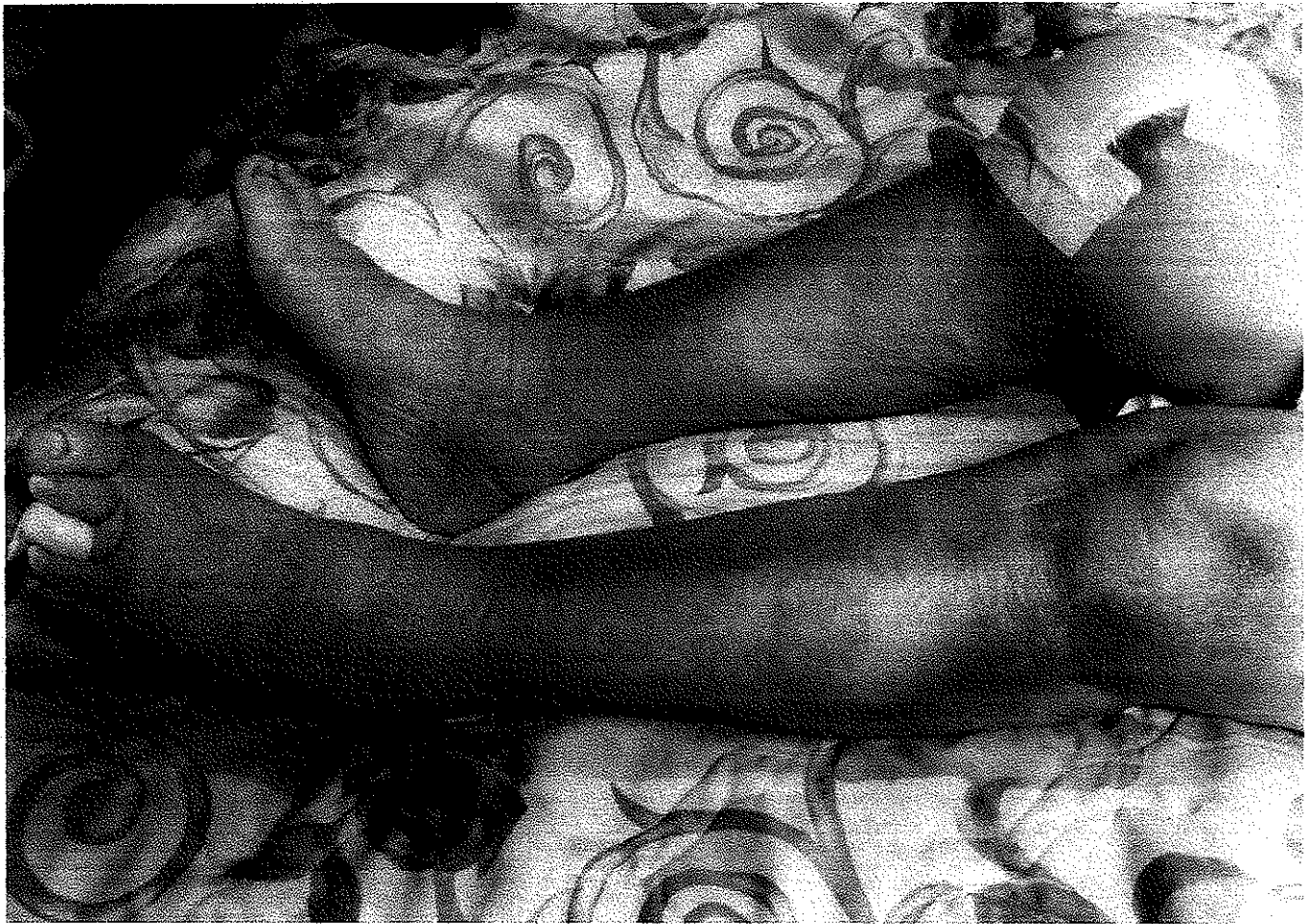PATIENT: S [redacted]

ROOM#: 1810

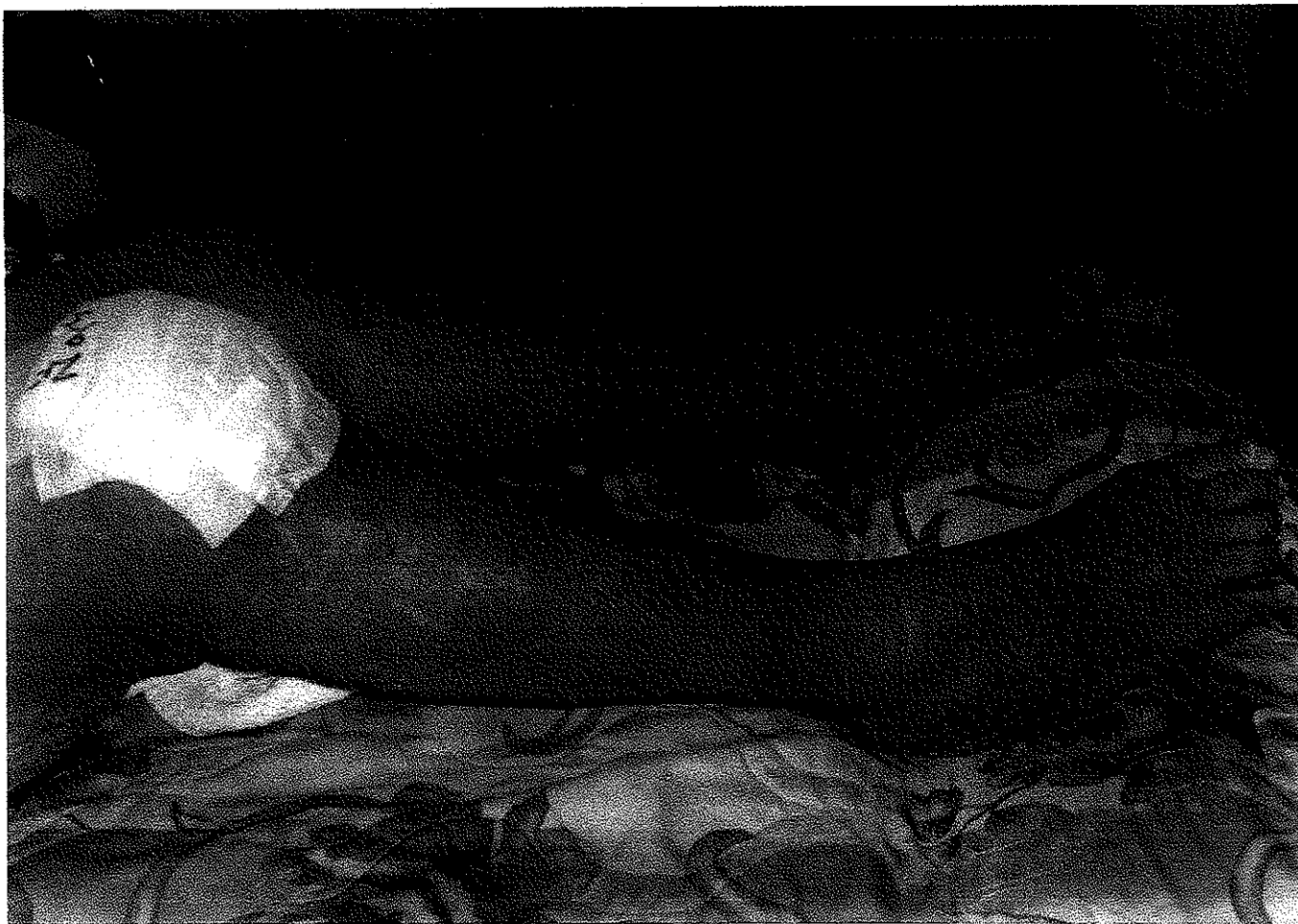DATE: 8-7-07

8/20/07





9/10/07



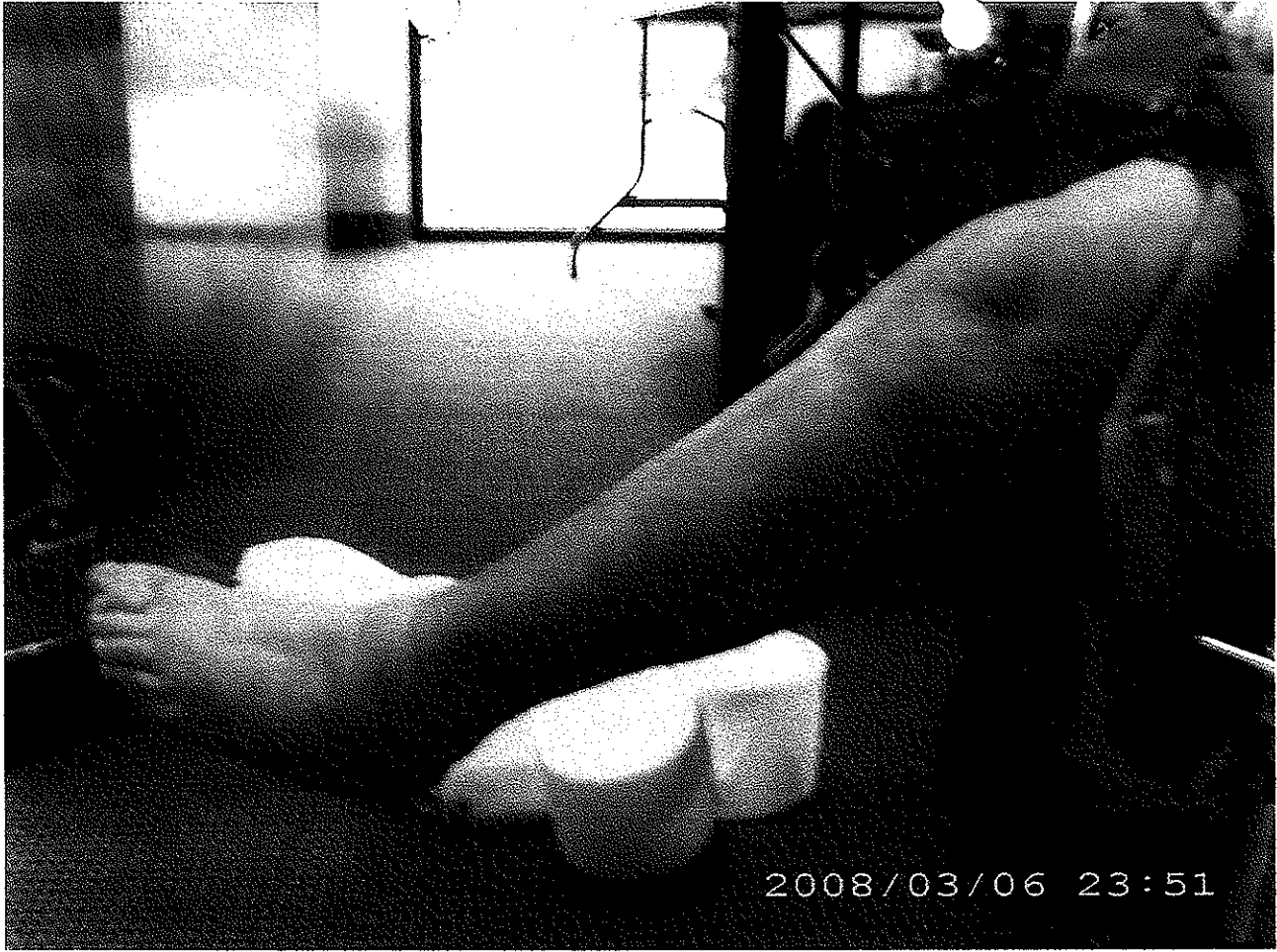9/10/07

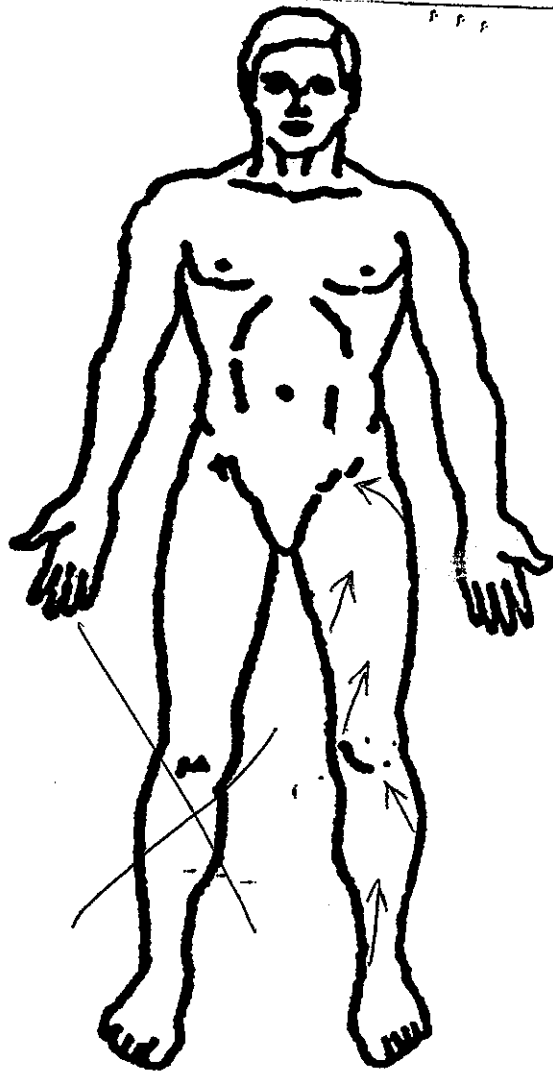
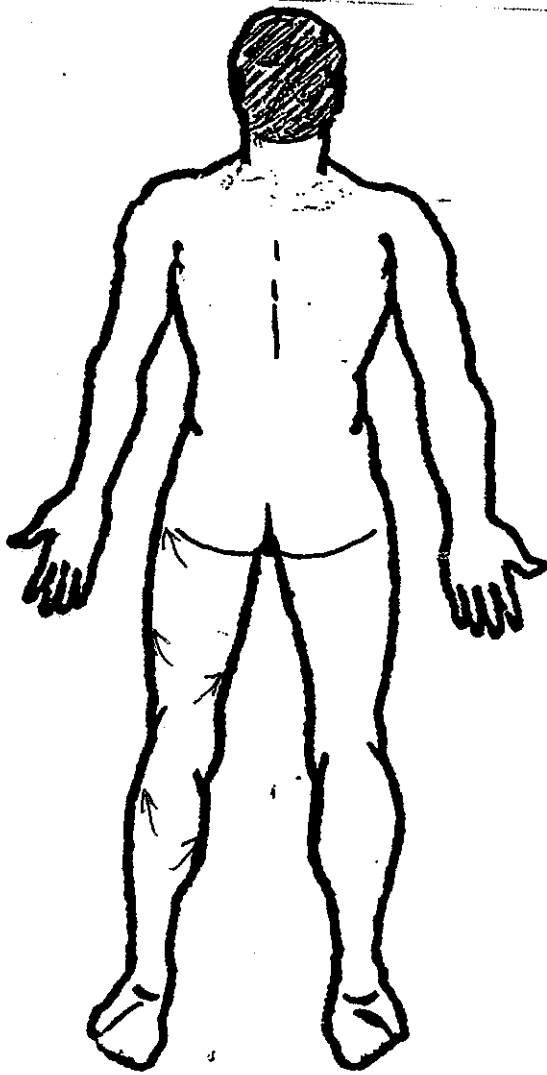
	Date	8/30/07	Date	9/5/07	Date	9-12-07		9/19
	Left	Right	Left	Right	Left	Right	Ⓐ	Ⓑ
0	26	25	25.5	24.5	25	24.5	24	23.5
4								
8	28	26	25.5	25	27.5	25	26.5	27
12								
16	27	26	25.5	23.5	23.5	23.5	23	22
20								
24	31	30.5	29	26	27.5	24	28.5	24.5
28								
32	37	35.5	35	33	33	31	34	31
36								
40	39	39	38	35.5	36.5	37	35.5	37
44								
48	47	51	47	50	46	49	47	46
52								
56								
60								
64								
68								
72								
TOTAL	235	233	225.5	217.5	219	214	218	213
	↓15.5	↓23	↓25	↓38.5	↓31.5	↓42cm	↓32.5	↓43

PATIENT NAME: [REDACTED]
THERAPIST: Paula Noyes OTR/LC

11

Q





REDNESS 

EDEMA 

WOUND 

FIBROSIS 

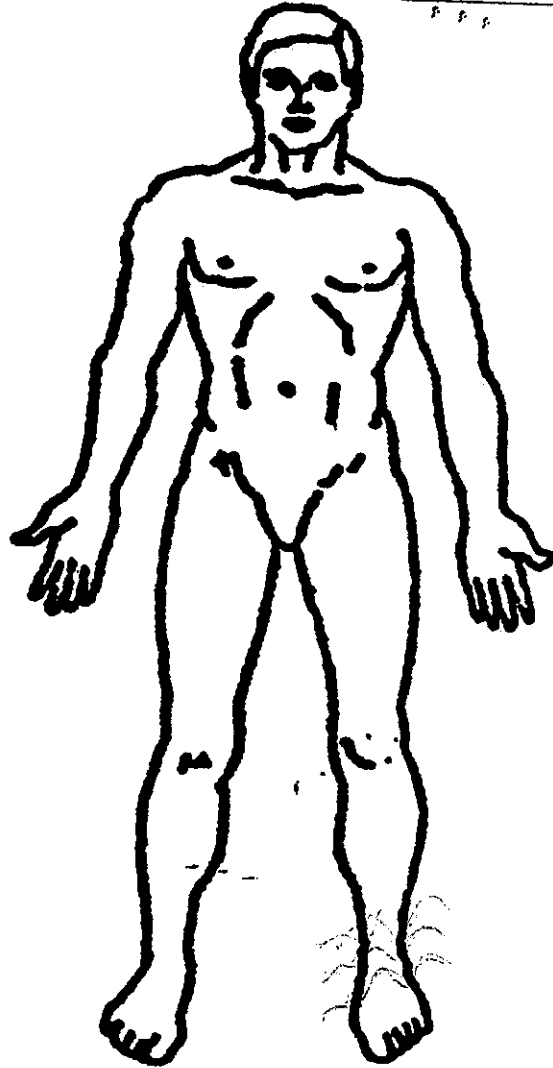
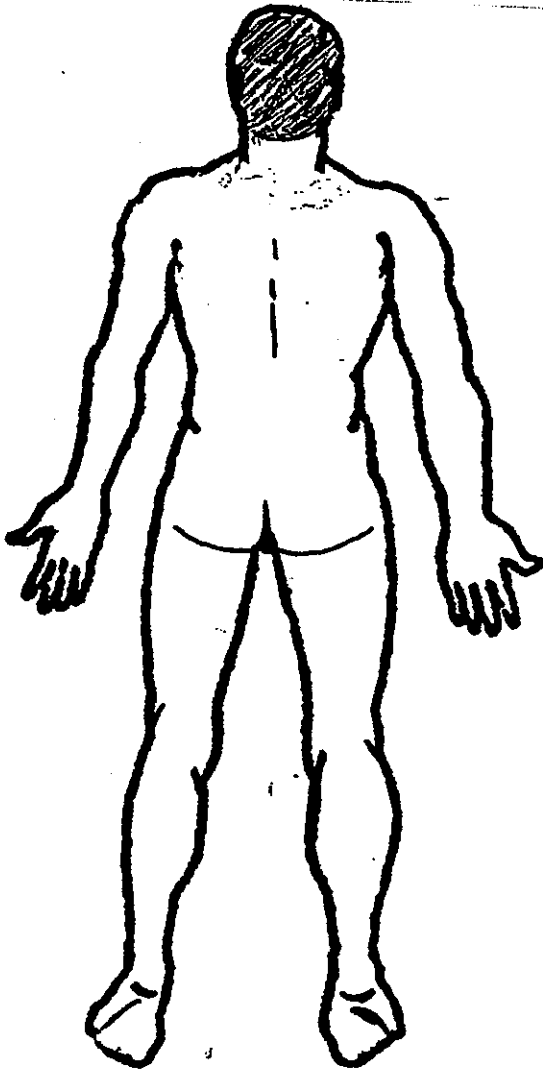
BRUISE 

SCAR 

PATIENT: E. J.

ROOM#: _____

DATE: 3/6/08



REDNESS 

EDEMA 

WOUND 

FIBROSIS 

BRUISE 

SCAR 

PATIENT: E.S. **ROOM#:** _____

DATE: 8-22-08

The information included in this case study
is accurate and true to the best of my
knowledge.

A handwritten signature in cursive script that reads "Paula Noyes OTR LLCC". The signature is written in black ink and is centered on the page.

Paula Noyes OTR LLCC