

Applications of Lymph Drainage Therapy For Dental Surgery and Mercury Toxicity

by Arlene Garcia, LMT

I recently saw Jackie* a 55 years old female. In 1997 Jackie had root canals and amalgam fillings removed with insufficient detoxification therapy. This resulted in dormant mercury toxicity and a closed off infection in the lower jawbone, which remained such until November 2007 when she began the process of replacing her resin crowns.

Her dentist put her on antibiotics for over 21 days and the infection persisted. She went to her D.O. and received Micro Current Therapy. This reduced the severe nerve pain in the lower jaw. The D.O. diagnosed mold and fungus present in the bone and she received treatments including Suisse Neural Therapy, chelation Therapy and essential oils. Her Dr. referred her to come to me for LDT treatments to help move the Chelation through her system. She had not been able to go to work for one week when she presented in my office.

Evaluation/Assessment:

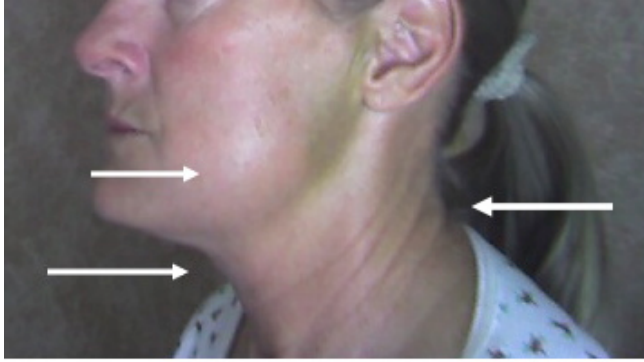
Jackie presented in my office on December 5, 2006 with severe swelling of the left side of her face extending into the neck and submandibular areas. Bright green bruising was evident along the left parotid region extending to the subangulomandibular zone. She also had pin in her left ear rated a 9/10 scale. She could not open her mouth more than a half-inch, and the left side of her lips did not move when she smiled. She felt fatigued, mental foginess she expressed like being hit by a Mac truck.

The initial Manual Lymph Mapping (MLM) assessment revealed congestion of the left inferior spinal accessory chain, jugulodigastric nodes, subangulomandibular nodes, parotids and left side of the face. Intra-oral MLM revealed inflammation and congestion of the jawbone and tissue surrounding both the upper and lower first molars, as well as the inner cheek.

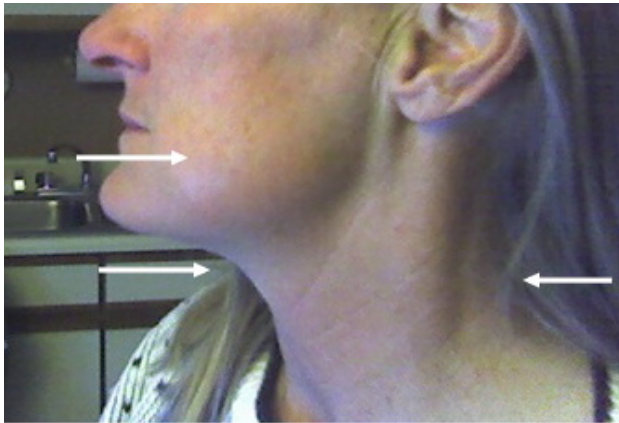
LDT Treatments/Outcomes:

Each treatments included LDT protocols for opening the clavicles, thoracic duct, liver, neck lymph areas (such as spinal accessory node chains, SCM chains, parotids,, posterior auriculars etc.), and release of the superficial face. Intra-oral LDT protocols were followed for the entire mouth to include tissue and bone. MLM was utilized in all treatments, as well as switching and second rhythm strokes when indicated.

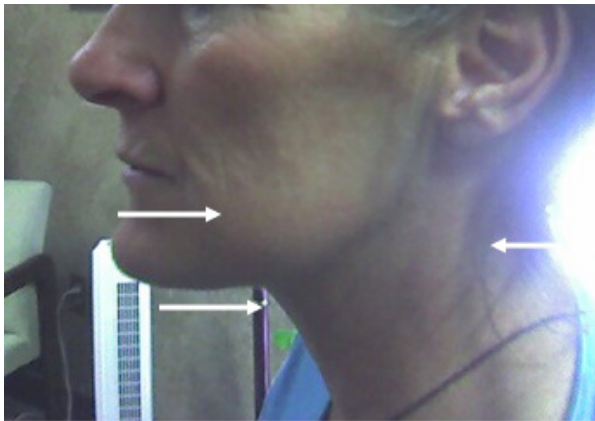
There were visible changes during each LDT treatment. You can observe the rapid decrease in the neck circumference and jaw edema in the following photos.



1st treatment, 12-5-2006



2nd treatment, 12-8-2006



3rd treatment 12-15-2006

After the first three treatments Jackie's face looked 90% better. Minor swelling was still visible in the lower jaw at the infection site. All bruising and ear pain

were eliminated. Frankie was able to open her jaw to complete extension, and her smile was symmetrical. She was feeling well enough to return to work full time.

Jackie continues to combine therapies from her Doctor and me. The infection in the jaw took seven months to clear completely. There are no traces of the mold and fungus in her system to date. Slight traces of mercury are still present. Her face has been restored to its normal appearance and function. Frankie is now retired and enjoys working on her horse ranch.

*Name changed for confidentiality.